

Basic MR imaging

Tissue Signal Characteristics

Signal in MR images is high or low (bright or dark), depending on the pulse sequence used, and the type of tissue in the image region of interest. The following is a general guide to how tissue appears on T1- or T2- weighted images.

Dark on T1-weighted image:

- Increased water, as in edema, tumor, infarction, inflammation, infection, hemorrhage (hyperacute or chronic)
- Low proton density, calcification
- Flow void

Bright on T1-weighted image:

- Fat
- Subacute hemorrhage
- Melanin
- Protein-rich fluid
- Slowly flowing blood
- Paramagnetic substances: gadolinium, manganese, copper
- Calcification (rarely)
- Laminar necrosis of cerebral infarction

Bright on T2-weighted image:

- Increased water, as in edema, tumor, infarction, inflammation, infection, subdural collection
- Methemoglobin (extracellular) in subacute hemorrhage

Dark on T2-weighted image:

- Low proton density, calcification, fibrous tissue
- Paramagnetic substances: deoxyhemoglobin, methemoglobin (intracellular), iron, ferritin, hemosiderin, melanin
- Protein-rich fluid
- Flow void

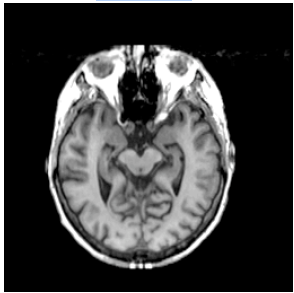
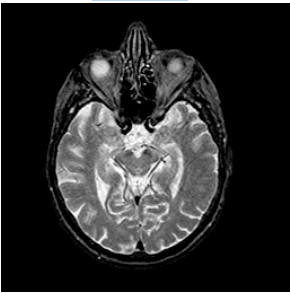
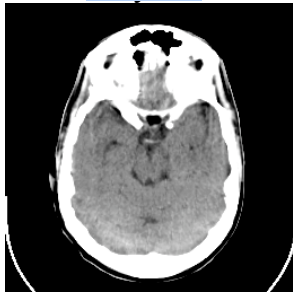
MR signal sources

- When protons are placed in a magnetic field, they oscillate.
- The frequency at which they oscillate depends on the strength of the magnetic field.
- Protons are capable of absorbing energy if exposed to electromagnetic energy at the frequency of oscillation. After they absorb energy, the nuclei release or reradiate this energy so that they return to their initial state of equilibrium. This reradiation or transmission of energy by the nuclei as they return to their initial state is what is observed as the MRI signal.
- The return of the nuclei to their equilibrium state does not take place instantaneously, but rather takes place over some time.
- The return of the nuclei to their initial state is governed by two physical processes:
 - The relaxation back to equilibrium of the component of the nuclear magnetization which is parallel to the magnetic field, and
 - The relaxation back to equilibrium of the component of the nuclear magnetization which is perpendicular to the magnetic field.
- The time that it takes for these two relaxation processes to take place is roughly equal to:
 - Time T1 for the first process, and
 - Time T2 for the second process.
- The strength of the MRI signal depends primarily on three parameters.
 - Density of protons in a tissue: The greater the density of protons, the larger the signal will be.
 - T1
 - T2
- The contrast between brain tissues is dependent upon how these 3 parameters differ between tissues.
- For most “soft” tissues in the body, the proton density is very homogeneous and therefore does not contribute in a major way to signal differences seen in an image.
- However, T1 and T2 can be dramatically different for different soft tissues, and these parameters are responsible for the major contrast between soft tissues.
- T1 and T2 are strongly influenced by the viscosity or rigidity of a tissue. Generally speaking, the greater the viscosity and rigidity, the smaller the value for T1 and T2.
- It is possible to manipulate the MR signal by changing the way in which the nuclei are initially subjected to electromagnetic energy. This manipulation can change the dependence of the observed signal on the three parameters: proton density, T1 and T2. Hence, one has a number of different MR imaging techniques (“weightings”) to choose from, which accentuate some properties and not others.

Neuroimaging

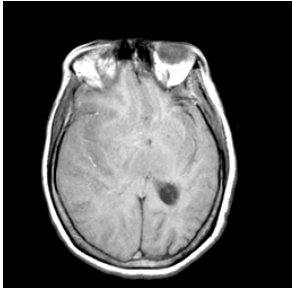
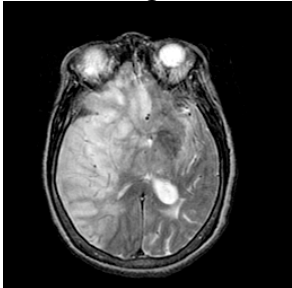
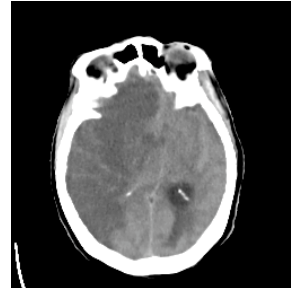
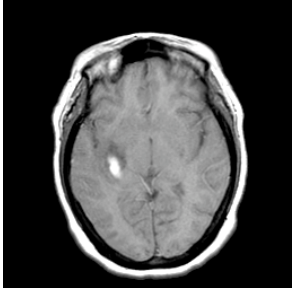
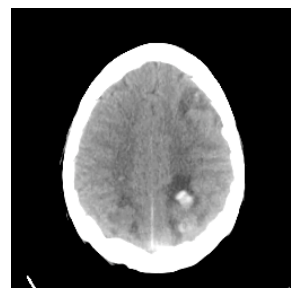
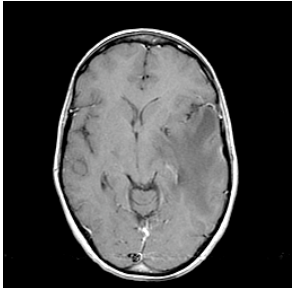
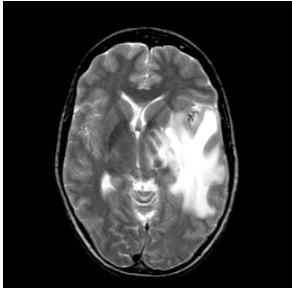
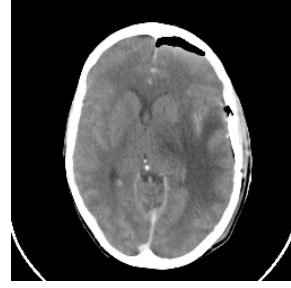

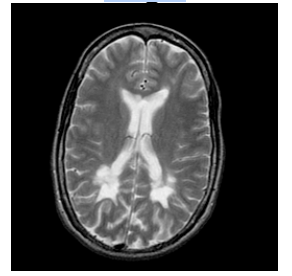
A simplified tabulation of tissue image characteristics:

Normal Tissue

	MR-T1 ¹	MR-T2 ¹	Xray-CT ²
			
Dense bone	Dark	Dark	Bright
Air	Dark	Dark	Dark
Fat	Bright	Bright	Dark
Water	Dark	Bright	Dark
Brain	Anatomic ³	Interm.	Interm.

1. Bright means high signal intensity, dark means low, and interm. means intermediate.
2. Bright means high density/high attenuation of X-rays, dark means low.
3. Grey matter appears grey, white matter white.

Abnormal Tissue

	MR-T1	MR-T2	X-ray-CT	Enhancement ¹
<u>Infarct</u>	Dark 	Bright 	Dark 	Subacute
<u>Bleed</u>	Bright ² 	Bright ²	Bright 	No
<u>Tumor</u>	Dark 	Bright 	Dark ³ 	Yes
<u>MS plaque</u>	Dark 	Bright 	Dark ⁴	Acute

1. Blood brain barrier leak. For MR, gadolinium; for CT, iodinated contrast material.

2. Unless very fresh or very old.

3. Unless calcified.

4. Often isodense.